

Case Report: Treatment of A Forty Six Year Old Male With Lateral Epicondylitis

Reginald W Kapteyn, DO, MA, BA
Orthopedic Associates of Muskegon, Muskegon, MI

Patient History

A 46-year-old, athletically active male had persistent symptoms for over 6 months. He had tried physical therapy, received one steroid injection, and was taking NSAIDs for pain management.

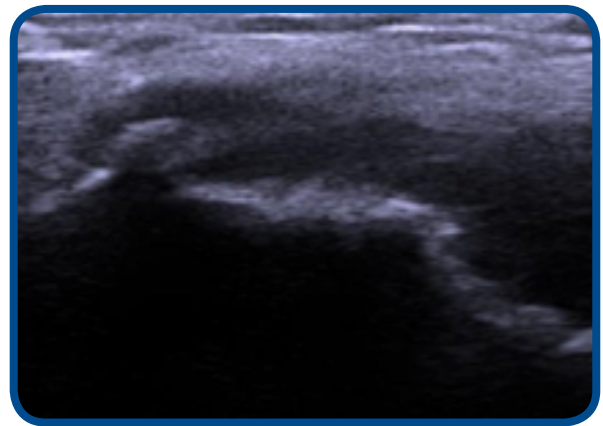
Treatment

The patient was eager to have this resolved and opted to undergo a percutaneous tenotomy using the TenJet device instead of open or arthroscopic procedure. Under ultrasound guidance, TenJet device was run for 3 minutes at setting 8 on the HydroCision HydroSurgery console.

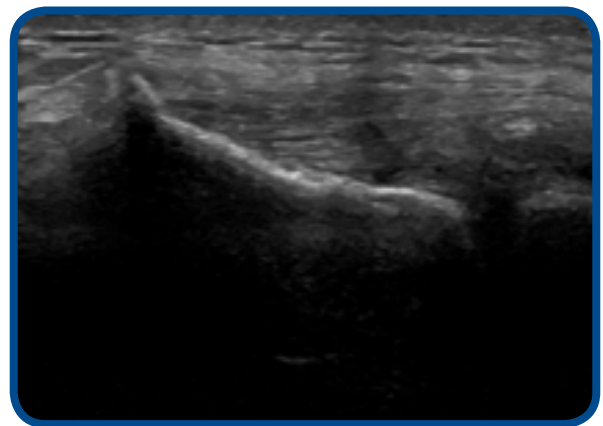
Follow Up

Patient was prescribed physical therapy with eccentric loading after the 2 week follow-up visit for a period of 4 weeks. VAS pain scores for this patient improved from 7 at baseline to 4 at 2 weeks and 1 at 6 weeks. Patient remained pain free at 3 and 6 months. PREE function scores improved 42% at 2 weeks, 89% at 6 weeks, and 100% at 3 and 6 months.

Preoperative diagnostic ultrasound imaging shows a small area at the lateral epicondyle of hyper echoic calcific debris within the lateral most insertion of extensor tendon, and 6 month follow up ultrasound shows a small enthesophyte off the lateral epicondyle, but no hyper or hypoechoic tendon.



Preoperative



Postoperative 6 Months