

Case Report: Treatment of A Fifty Five Year Old Female With Lateral Epicondylitis

Reginald W Kapteyn, DO, MA, BA
Orthopedic Associates of Muskegon, Muskegon, MI

Patient History

A 55-year-old female with persistent symptoms for 3 years had undergone extensive conservative treatment that included activity modification, NSAIDs, elbow straps, and 3 to 4 steroid injections.

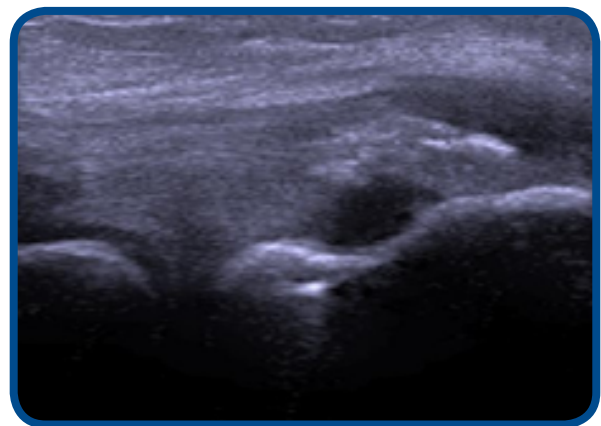
Treatment

Patient was consented to performing ultrasound guided percutaneous tenotomy using the TenJet[®] device instead of open or arthroscopic surgery. After identifying the defect on ultrasound, the procedure was performed for 4 minutes at setting 8 on the HydroCision[®] HydroSurgery console.

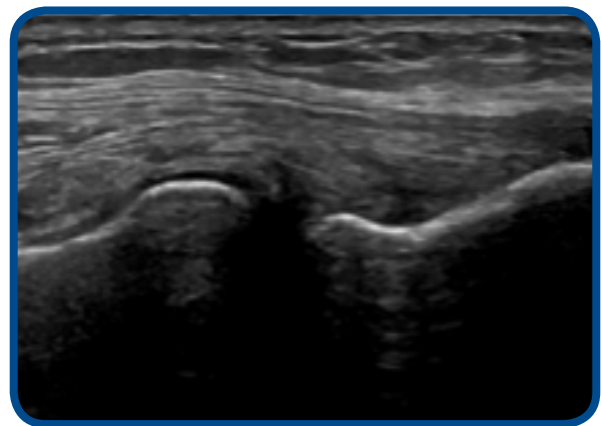
Follow Up

Patient was prescribed physical therapy with eccentric loading after the 2-week follow-up visit for a period of 4 weeks. VAS pain scores improved from 5 at baseline to 2 at 2 weeks, and 0 at 6 weeks. Patient remained pain free at 6 months. PREE function scores improved 43% at 2 weeks, 99% at 6 weeks, and 100% at 6 months.

Preoperative diagnostic ultrasound imaging shows a large area of mixed hyper and hypoechoic appearance consistent with calcific tendinosis, the light area being calcified tendon, and the dark area liquefied necrotic tendon. The ultrasound image at 6 month follow-up, shows complete resolution of the calcific debris, with minimal hypoechoic necrotic tendon.



Preoperative



Postoperative 6 Months